

# Arthroscopic Rotator Cuff Repair: 4- to 10-Year Results

Eugene M. Wolf, M.D., William T. Pennington, M.D., and Vivek Agrawal, M.D.

---

**Purpose:** The purpose of this article is to report the 4- to 10-year results of arthroscopic repair of full-thickness rotator cuff tears. **Type of Study:** This is a retrospective study evaluating a series of arthroscopic rotator cuff repairs performed by a single surgeon from February 1990 to February 1996. **Methods:** Retrospective chart reviews and telephone interviews were performed to evaluate the results of arthroscopic repair of rotator cuff tears. Results were evaluated using a modified University of California, Los Angeles (UCLA), shoulder scoring system. **Results:** One-hundred five arthroscopic rotator cuff repairs were performed in 104 patients between February 1990 and February 1996. Of these, 95 patients (96 shoulders) were available for follow-up evaluation at the time of this review. The mean UCLA score of all shoulders involved was 32. Fifty-one patients showed excellent results; 39, good; 2, fair; and 4, poor according to the modified UCLA scoring system. In no case was any loss of motion noted as a result of the surgical intervention. **Conclusions:** This retrospective study is the largest series of arthroscopic rotator cuff repairs with the longest period of follow-up thus far reported. Of the patients available for follow-up evaluation, 94% of patients qualified as a good to excellent result according to the UCLA shoulder scoring system. This study shows that patients treated with this arthroscopic rotator cuff repair technique have maintained excellent clinical outcomes 4 to 10 years after surgery. **Level of Evidence:** Level IV. **Key Words:** Arthroscopic rotator cuff repair—Shoulder arthroscopy—Rotator cuff tear.

---

In 1911, Codman<sup>1</sup> first described the open surgical repair of a supraspinatus tendon rupture that he identified as one of the major causes of the painful shoulder. He advocated a deltoid splitting technique that did not include an acromioplasty. Rotator cuff pathology is a common shoulder disorder experienced in the orthopaedic patient population. The spectrum of these disorders ranges from inflammation to massive tearing of the rotator cuff musculotendinous unit. Since Codman's first cuff repair, surgical techniques have continually evolved in an effort to achieve an optimal outcome in the patient with a symptomatic disruption of the rotator cuff. The advent of shoulder arthroscopy prompted orthopaedic surgeons to explore

new techniques, including arthroscopic assisted "mini-open" techniques and purely arthroscopic techniques.

The first arthroscopic cuff repairs were reported by Johnson using a staple technique.<sup>2</sup> Although successful, this technique had the disadvantage of placing a metal staple in the greater tuberosity and subacromial space. This produced the need for secondary surgical procedures for staple removal but did allow for second looks that showed remarkable healing in most cases. With the introduction of Mitek suture anchors (Mitek Surgical, Westwood, MA) in 1989, the senior author (E.M.W.) developed an arthroscopic technique that paralleled standard suturing techniques of open rotator cuff repairs, and performed the first completely arthroscopic suture repair in February 1990.<sup>3</sup> The purpose of this paper is to evaluate the 4- to 10-year clinical results in patients who underwent all-inside arthroscopic repair of a rotator cuff disruption by a single surgeon.

## METHODS

One hundred and five consecutive arthroscopic rotator cuff repairs in 104 patients were performed by

---

*From the California Pacific Medical Center (E.M.W.), San Francisco, California; St. Luke's Medical Center (W.T.P.), Milwaukee, Wisconsin; and Central Indiana Orthopedics (V.A.), Muncie, Indiana, U.S.A.*

*Address correspondence and reprint requests to Eugene M. Wolf, M.D., 3000 California St, San Francisco, CA 94115, U.S.A. E-mail: genewolfmd@aol.com*

*© 2004 by the Arthroscopy Association of North America  
0749-8063/04/2001-2705\$30.00/0  
doi:10.1016/j.arthro.2003.11.001*

**TABLE 1.** *Modified UCLA Shoulder Rating Scale*

Patient Satisfaction	
0	Patient feels procedure was not successful
5	Patient feels procedure was a success
Active Forward Flexion	
Range of Motion	
0	<30°
1	30°-45°
2	45°-90°
3	90°-120°
4	120°-150°
5	>150°
Strength of Forward Flexion	
0	No active contraction
1	Evidence of slight muscle contraction, no active elevation
2	Complete active forward flexion with gravity eliminated
3	Complete active forward flexion against gravity
4	Complete active forward flexion against gravity with some resistance
5	Complete active forward flexion against gravity with full resistance
Pain	
1	Present always and unbearable; strong medication, frequently
2	Present always, but bearable; strong medication, occasionally
4	None or little at rest, present during light activities; salicylates, frequently
6	Present during heavy or particular activities only; salicylates, occasionally
8	Occasional and slight
10	None
Function	
1	Unable to use limb
2	Only light activities possible
4	Able to do light housework or most activities of daily living
6	Most housework, shopping, and driving possible; able to do hair and to dress and undress, including fastening brassiere
8	Slight restriction only; able to work above shoulder level
10	Normal activities
Excellent	34-35
Good	28-33
Fair	21-27
Poor	0-20

the senior author over a 6-year period between February 1990 and February 1996. Nine patients were lost in the follow-up period, leaving 96 shoulders in 95 patients available for evaluation, with an average follow-up time of 75 months (range, 48-122 months). Patients included 60 men and 35 women, and the average age at surgery was 57.6 years (range, 31-80 years). Conservative therapy failed in all patients, and they continued to experience unacceptable pain and weakness in the affected shoulder.

All patients were clinically evaluated by the senior author (E.M.W.). An independent follow-up telephone evaluation of all patients was then performed by another author (W.T.P.). Patients were evaluated using the modified University of California, Los Angeles (UCLA), rating system. UCLA shoulder scores were used as the primary measure of outcomes (Table 1).

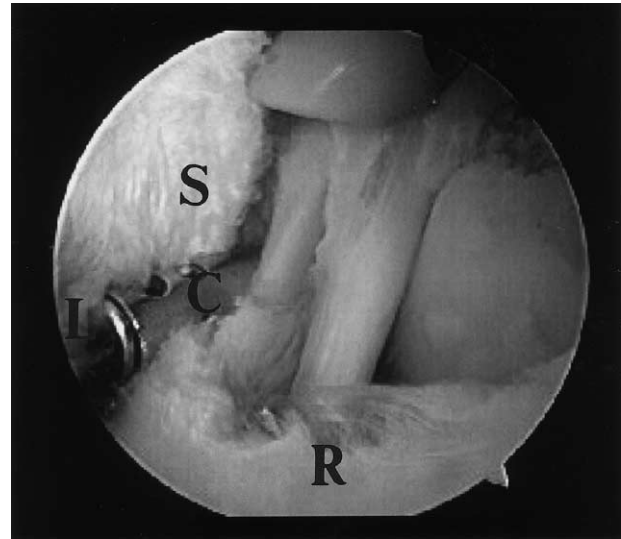
Seventy-seven percent of patients had repairs of the dominant shoulder, with 74 right and 22 left repairs. All patients also had arthroscopic subacromial decompressions. Eighteen patients had other procedures performed concurrently, including 9 arthroscopic Mumford procedures, 1 SLAP lesion repair, 2 SLAP lesion debridements, 1 debridement of a biceps tendon rupture, 1 capsular plication, 1 open Bristow procedure, and 3 os acromiale excisions. These 18 patients were initially excluded to preserve a uniform study population. However, because the clinical outcomes were identical with and without these patients, they were included.

### Surgical Technique

The rotator cuff repairs were performed with the patient in the lateral decubitus position. In all cases,

the glenohumeral joint was inspected to evaluate for any significant intra-articular pathology. The cuff was first inspected from the articular side, and the margins of the torn rotator cuff tendons were debrided in an effort to remove any devascularized or synovialized tissue. An arthroscopic subacromial decompression was then performed in all cases. The subacromial decompressions were conservative in nature, with care taken to preserve as much of the coracoacromial arch as possible. The undersurface of the acromion was stripped of soft tissues with electrocautery. A burr was used to perform the acromioplasty by reducing the anteroinferior prominence, while leaving the coracoacromial ligament intact. The next step was the excision of the bursal tissue in the subacromial space that covers the cuff tendons, especially in the anterior and posterior recesses of the subdeltoid bursa. This was essential to evaluate the extent of the tear and the degree of involvement of the different rotator cuff tendons. The bursectomy was also necessary to facilitate visualization of the tips of suture hooks where they exit the cuff during suture repair. In large tears, visualizing the base of the spine of the scapula as it courses medially is also necessary. This was achieved by removing the fibrofatty tissue between the cuff and the scapular spine. In cases of large tears, this approach allowed us to trace the muscle tendon units medially, thereby better identifying the tendons and better determining the anatomic placement on the footprint of the tuberosity.

Next, the mobility of the rotator cuff was evaluated by approximating the tear margins to the tuberosity with a grasper or nerve hook. A blunt nerve hook is an excellent tool for this purpose. The blunt tip was used to puncture a point on the margin of the tendon and advance it toward the tuberosity. If necessary, the cuff was further mobilized by freeing it from the undersurface of the acromion or cutting the capsule on the articular side around the superior pole of the glenoid with an elevator, shaver, or radiofrequency device. The region of the greater tuberosity of the humerus was then abraded with a full-radius shaver, and a burr was used to create a bed of bleeding bone to promote healing of the reattached cuff. The excursion of the stump of the cuff when completely mobilized determines the exact area of preparation. An attempt was made to fit the cuff into an abraded and recessed area of the tuberosity. All sutures were simple in nature and were used to drag the cuff over the abraded bed to anchors that were placed in undisturbed tuberosity bone lateral to the bed. Placement of anchors directly into an area of tuberosity bone that has been weakened

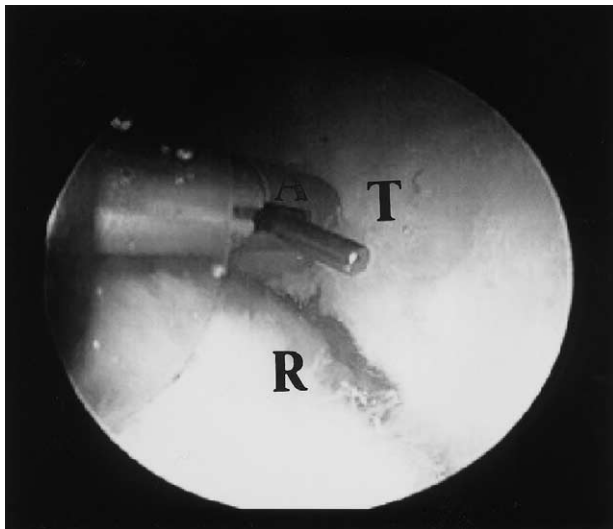


**FIGURE 1.** This arthroscopic visualization of a large crescent shaped tear (R) from the subacromial space through the posterior viewing portal. The outflow cannula (C) is lying between the frayed CA ligament (L) and overlying anterior subacromial spur (S). The standard 5-mm universal cannula is seen placed through the mid-lateral portal and is used for CA ligament recession from the anterior rim of the acromion as well as to strip any soft tissue from the undersurface of the acromion before arthroscopic subacromial decompression.

through the use of a burr on its surface is an invitation to suture anchor pullout.

Each tear was assessed and repaired with a side-to-side, end-to-bone, or combination of side-to-side and end-to-bone configurations. The most common configuration was a combination of side-to-side and end-to-bone. These were always relatively large tears that had a soft tissue margin greater than the bony (tuberosity) margin. We used an “L” or “Y” shaped configuration to equalize the soft tissue and bony margins and avoid “dog ears” at the site of the repair. Side-to-side repairs are technically simple and were all performed using a Crescent suture hook (Linvatec, Largo, FL) and No. 1 PDS suture. They were performed where a relatively narrow “V” or “U” shaped tear occurred. All repairs are performed purely arthroscopically using variously shaped suture hooks (Linvatec). An average of 4 sutures (range, 1-8 sutures) and 1.2 suture anchors (range, 0-4 anchors) were used per cuff repair. A clinical example of an end-to-bone repair of a large crescent-shaped tear is depicted in Figs 1-3.

Repairs were performed exclusively with absorbable PDS sutures in 79% of repairs, nonabsorbable sutures in 15%, and a mixture of PDS and Ethibond



**FIGURE 2.** The arthroscope is switched to use the mid-lateral portal for viewing during the repair process. This figure illustrates the insertion of a rotator cuff anchor (A) (Mitek, Westwood, MA) into the previously abraded tuberosity (T) through a threaded 8.4-mm working cannula (Arthrex, Naples, FL). Before anchor insertion, a No. 1 PDS suture was passed through the edge of the tendon stump (R) with a suture passer. The leading end of the passed suture is inserted through the eyelet of the anchor before its insertion into the tuberosity of the humerus.

(Ethicon, Somerville, NJ) in 6%. This includes 64 shoulders repaired with No. 1 PDS, 11 shoulders with No. 0 PDS, and one shoulder with 2-0 PDS. Ten shoulders were repaired with nonabsorbable No. 2 Ethibond and 6 shoulders with a mixture of Ethibond and PDS. Three repairs were performed with No. 2 Tevdek (Deknatel, Fall River, MA) and one repair was done with No. 2 Mersilene (Ethicon).

Postoperatively, patients were placed in a simple immobilizer for 6 weeks. No abduction or airplane splints were used. Patients were allowed immediate use of the arm with instructions to keep the elbow at the side. The patient was instructed to remove the bulky dressing applied in the operating room on the morning after surgery and apply adhesive bandages to the portal sites. No active elevation, pushing, pulling, or lifting was allowed for 6 weeks. Pendulum and pulley exercises were begun at the first postoperative visit (5 days) or as soon as tolerated.

## RESULTS

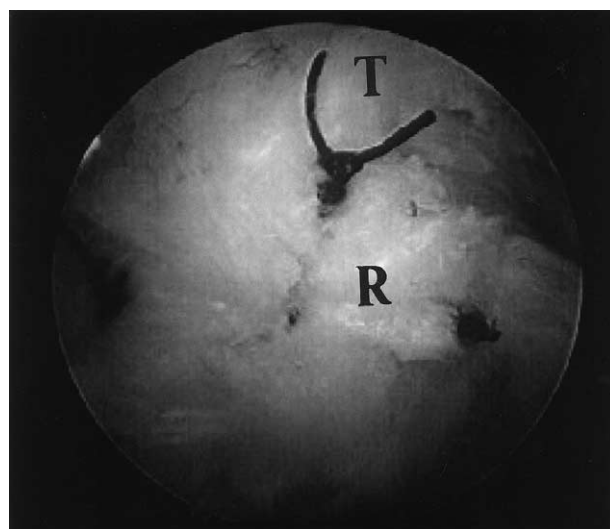
Ninety-four percent of patients had good and excellent postoperative scores, with 51 excellent (53%), 39 good (41%), 2 fair (2%), and 4 poor results (4%). The average UCLA score was 32. Ninety-one of the 95

patients evaluated (96%) rated the surgery as successful and were satisfied with the repair. Four patients rated the surgery as unsuccessful.

The UCLA shoulder scoring system for strength, pain, and function were evaluated (Table 1). The mean response in all patients grading the strength was 4.6 (range, 2-5), mean response for pain was 8.8 (range, 2-10), and mean perceived function grade was 9.3 (range, 1-10). The average grade for forward flexion of the shoulder was 4.9 (range, 1-5). This was a retrospective study, and no preoperative scores were available for comparison.

No statistically significant difference in total UCLA scores was found when comparing repairs performed with absorbable and those with nonabsorbable sutures. The mean UCLA score for nonabsorbable sutures was 32.2 versus 32.5 for repairs with absorbable sutures ( $P < .63$ ). Ninety-three percent of the patients repaired exclusively with PDS qualified as having a good or excellent result, and 91% of patients repaired with exclusively nonabsorbable or a mixture of PDS with nonabsorbable suture had a good or excellent result.

In 3 patients, this arthroscopic repair was a revision of a previous open rotator cuff repair. The mean UCLA score in these patients was 32.3 (range, 30-35). Five of the patients in the entire series had arthroscopic repair performed with a previous arthroscopic assisted mini-open repair performed on the contralat-



**FIGURE 3.** This final arthroscopic photograph taken from the mid-lateral working portal shows the anatomic reapproximation of this large crescent-shaped tear (R) to the tuberosity (T) of the humerus. The repair was performed with 3 No. 1 PDS sutures with 3 Mitek rotator cuff anchors anchoring the torn cuff anatomically.

eral shoulder. All of these patients stated that they were more satisfied with the side in which the arthroscopic repair was performed. They noted the perception of a quicker period of recovery and return to function than with the open repair.

Six patients rated the outcomes as fair or poor at the time of this study. Initial treatment failed in all 6 patients. One of these patients underwent a Bristow procedure at the index operation. Although this patient was satisfied with the procedure originally, he has experienced recent progression of shoulder pain, worsening clinical outcome. Despite subsequent secondary procedures in the other 5 with failure of the index operation, only one of these patients has progressed to a satisfactory clinical outcome.

## DISCUSSION

Published series of open rotator cuff repair of full-thickness tears have reported good results in 71% to 92% of patients, improving pain, function, and strength.<sup>4-12</sup> Several authors have recommended arthroscopic subacromial decompression alone without rotator cuff repair in select older patients with reported outcomes of 77% to 88% good and excellent results.<sup>13-15</sup> Anatomic studies of elderly cadavers have shown asymptomatic rotator cuff tears that occur by attrition.<sup>16,17</sup> Pain in these less-demanding patients may be relieved by decompression of their impingement, regardless of the condition of their rotator cuff. Gartsman<sup>18</sup> and Ellman and Kay,<sup>14</sup> however, have had less success with decompression alone, and other researchers<sup>6,19</sup> have suggested that younger, more demanding patients require repair of the symptomatic rotator cuff tears.

Montgomery et al.<sup>20</sup> compared the efficacy of arthroscopic debridement and subacromial decompression with that of open repair for chronic full-thickness rotator cuff tears in a prospective randomized study. He compared results of 50 patients (average age, 58) with open repairs with those of 38 patients (average age, 66) with arthroscopic decompression alone at an average 2- to 5-year follow-up times and found 78% versus 61% satisfactory results. No correlation was identified among size of tear, patient age or activity level, and results achieved with arthroscopic decompression. Ogilvie-Harris et al.<sup>21</sup> prospectively studied 45 patients with arthroscopic subacromial decompression versus open rotator cuff repair and found pain relief with both, but better functional scores with cuff repair, although recovery was longer.

A number of researchers<sup>6-8,22-24</sup> have reported the

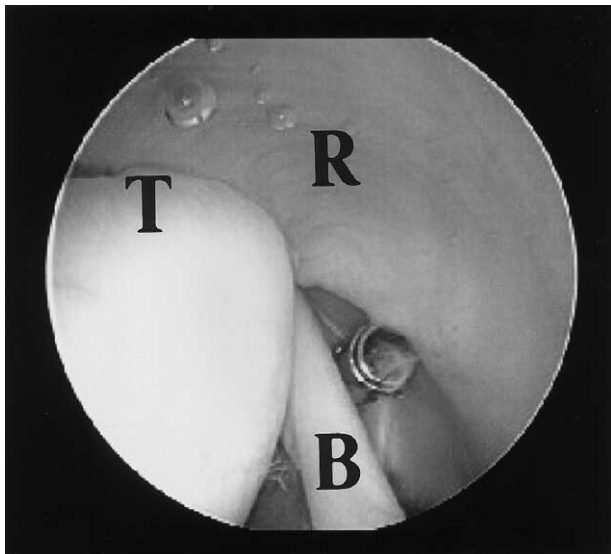
results of treatment of full-thickness rotator cuff defects by an arthroscopic assisted mini approach to avoid injury to the deltoid origin. In 1990, Levy et al.<sup>7</sup> reported results of 25 patients (age, 21-75) with a minimum of 1-year follow-up study after arthroscopic evaluation, subacromial decompression, debridement, and mobilization of full-thickness rotator cuff tears with open repair via a limited deltoid-splitting approach. They found 80% good and excellent results, based on the UCLA shoulder scale, with 3 small, 5 medium-sized, 15 large, and 2 massive-sized tears. Ninety-six percent of patients were satisfied with the procedure.

Paulos and Kody<sup>6</sup> later described their experience with an arthroscopically enhanced mini approach to full-thickness rotator tears, with 88% good and excellent results in 18 patients, with an average follow-up time of 48 months. They noted a dramatic decrease in pain and increase in function with associated increase in active forward flexion and strength. Patient satisfaction was 94%.

Liu and Baker<sup>8</sup> repaired 35 full-thickness rotator cuff defects with arthroscopic assistance and a deltoid-splitting incision with 85% good and excellent results and 92% patient satisfaction. In a second study by the same authors, no difference in results was reported between open and arthroscopically assisted rotator cuff repairs.<sup>12</sup>

Blevins et al.<sup>23</sup> evaluated the outcome of 78 arthroscopically assisted mini-open cuff repairs. Sixty-four patients were interviewed, and 47 of these patients returned for physical examination, with a follow-up duration of 12 to 65 months. They cited an 89% patient satisfaction rate with pain and function scores and active shoulder elevation increasing significantly after surgery.

Warner et al.<sup>24</sup> reported their results for 17 patients who underwent arthroscopic assisted rotator cuff repair with an average follow-up period of 25 months. Patients in that study showed no statistical difference in strength evaluation of abduction and external rotation when compared with the contralateral nonoperative shoulder, and 14 of the 15 patients (93%) available for follow-up evaluation rated the results as excellent. Therefore, in a review of the recent literature, a range of 80% to 94% is reported in treating patients with full-thickness rotator cuff defects with an arthroscopic assisted mini-open technique. Reviewing the English language literature yields reports by a number of researchers<sup>25-30</sup> reporting clinical results for treating full-thickness rotator cuff tears with a purely arthroscopic repair technique.



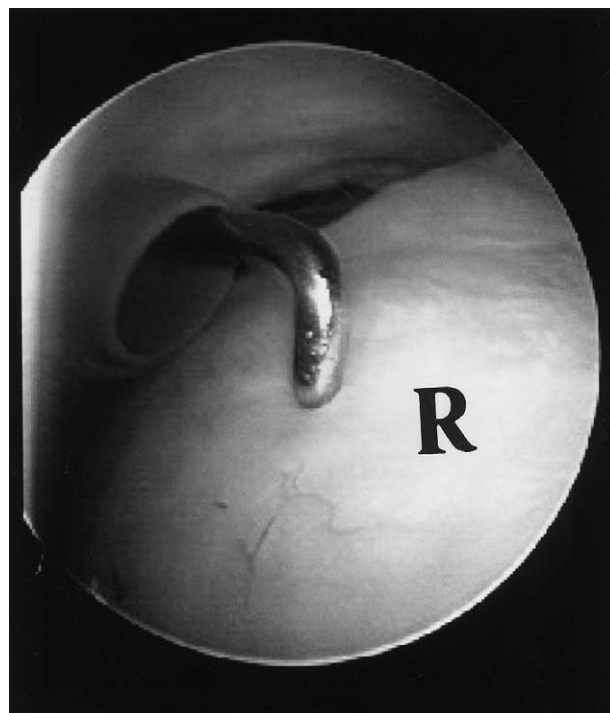**FIGURE 4.** Arthroscopic view through standard posterior viewing portal of the articular surface of the left rotator cuff in a patient 8 years after arthroscopic rotator cuff repair with 3 No. 1 PDS with a side-to-side closure technique. The intra-articular portion of the biceps long head of the biceps tendon (B) is seen just beneath the outflow cannula. The patient had an excellent result and was undergoing an arthroscopic Mumford procedure for anterior cruciate joint arthrosis that developed secondary to a type 2 acromioclavicular separation sustained in a motor vehicle accident 6 months before this procedure. The articular surface of the rotator cuff (R) appears normal at its attachment to the greater tuberosity (T) of the humerus.

In 1995, the senior author reported results on 54 shoulders after arthroscopic subacromial decompression and purely arthroscopic rotator cuff repair at an average of 27 months follow-up time (minimum, 1 year), with 85% good and excellent results. The arthroscopic approach allowed repair of several other associated lesions, and no complications with deltoid detachment occurred. Only 2 patients required a second repair for residual cuff defects, and 91% of the patients were satisfied with the procedure. This previous report also involved second-look arthroscopy in 23 patients, with 19 in the office and 4 in the operating room (Figs 4, 5). Sixteen repairs (70%) were intact on second-look arthroscopy, and 7 showed some communication with the subacromial bursa.<sup>25</sup> These results compared positively with previous studies evaluating the integrity of the rotator cuff after open repair techniques that showed residual rotator cuff defects in 34% to 90% of patients who previously underwent open rotator cuff repair.<sup>32-35</sup> Although a difference in UCLA shoulder scores was found between the intact and defective cuffs seen at second-look arthroscopy

(30.6 and 27, respectively) in our patients, several patients with communication to the subacromial bursa had good results, possibly because the tears had been reduced in size to within Burkhart et al.'s<sup>36</sup> rotator crescent. Liu and Baker<sup>8</sup> similarly found that the integrity of the cuff at follow-up evaluation does not determine the functional outcome of the treated shoulder.

Gazielly et al.,<sup>28</sup> in 1996, reported the results for 15 patients in whom arthroscopic rotator cuff repair was performed. These patients showed an increase in Constant and Murley scores from 58.1 preoperatively to 87.6 after arthroscopic repairs of full-thickness rotator cuff defects. Snyder et al.,<sup>29</sup> in 1996, reported on a series of 47 patients with an 87% good to excellent results after arthroscopic repair of full-thickness rotator cuff tears.

In 1998, Gartsman et al.<sup>26</sup> and Tauro<sup>27</sup> reported their results using an all-inside arthroscopic technique of rotator cuff repair with 90% and 92% good to excellent results, respectively. Proposed advantages of this technique by these authors include smaller incisions, access to the glenohumeral joint to address



**FIGURE 5.** Arthroscopic view of the same cuff's bursal surface 8 years after arthroscopic rotator cuff repair through the posterior viewing portal inserted into the subacromial space. The rotator cuff (R) is palpated with the probe through the mid-lateral portal, and no evidence of prior repair was noted.

concomitant intra-articular pathology, no need for detachment of the deltoid, and less soft tissue dissection. These authors also suggested that this technique resulted in a better cosmetic result, decreased postoperative pain, and more rapid gains in motion when compared with open surgical treatment of similar lesions.

In 1999, Weber<sup>30</sup> presented a study comparing arthroscopic repairs with mini open repairs. One hundred eighty patients were evaluated in this study; 151 patients underwent mini-open and 29 underwent completely arthroscopic repairs from 1991 to 1995. The author reported 87% good to excellent results in patients in this series. Twelve patients had an arthroscopic repair of the rotator cuff with contralateral open repair. All 12 of these patients rated the arthroscopically repaired side superior to the other side repaired by open techniques. Although no statistical data were presented to support this impression, the authors proposed another advantage of the arthroscopic repair to be decreased incidence of postoperative stiffness when compared with open techniques.

This is the largest series of arthroscopic rotator cuff repairs with the longest period of follow-up data reported to date. Our 94% good to excellent results at an average of 75 months (range, 48 to 122 months) compares favorably with previous reported results of arthroscopic and arthroscopically assisted mini-open rotator cuff repair. Suture type did not significantly affect our results, and the majority (79%) of repairs were performed with exclusively absorbable suture material.

We believe that the arthroscopic evaluation of the anatomy of the rotator cuff tear is an essential step in restoring the anatomy of the disrupted rotator cuff. Burkhart<sup>37</sup> eloquently described the concept of tear margin convergence of the rotator cuff disruption allowing reattachment of the cuff without creating a tension overload situation at any of the attachment sites. Burkhart stressed the importance of tear pattern recognition with the employment of side-to-side sutures when appropriate to create a situation of force-couple balancing to the repaired cuff when it is reattached to the tuberosity. Burkhart suggests that visualization of the tear from different arthroscopic portals allows the surgeon to obtain a 3-dimensional understanding of the tear pattern superior to that obtained by open means. We echo this sentiment in that arthroscopic repair of the rotator cuff allows a thorough evaluation of the complete anatomy of the cuff disruption. Furthermore, with each suture passed, the effect may be evaluated by direct visualization of the

suture's impact on the entire cuff. This allows for the evaluation for the creation of any inappropriate flaps or "dog-ears" that may signify the creation of a non-anatomic situation that may be doomed to failure over cyclic loading because of force-couple imbalance.

This study has admitted shortcomings. Although the UCLA shoulder scores are available 4 to 10 years postoperatively, this only signifies wellness at that moment. Ideally, scores during the preoperative period, with sequential scores during the perioperative period, would provide conclusive evidence of the direct effect of treatment on function of the shoulder. Because the outcomes assessment was performed via a detailed telephone interview, range of motion and strength determinations are admittedly subjective. Finally, a randomized, prospective clinical study with patients matched according to age, activity, and function and comparing completely arthroscopic to mini-open rotator cuff repairs would be required to advocate either method as superior.

The purpose of this study is to report our long-term results of all-inside arthroscopic rotator cuff repairs. Ninety-one of 95 (96%) patients treated using this method believed that this technique was successful in treating their rotator cuff tears. At 4 to 10 years after surgery, 94% of patients rated their results as good to excellent. We believe that this repair technique optimizes evaluation of the rotator cuff defect with a greater potential for anatomic restoration than with open methods. Arthroscopic rotator cuff repair can achieve a high level of good and excellent results with minimal morbidity and minimal violation of the surrounding soft tissue envelope.

## REFERENCES

1. Codman EA. Rupture of the supraspinatus tendon and other lesions in or about the subacromial bursa. In: *The shoulder*. Boston: Thomas Todd, 1934.
2. Johnson L. Arthroscopic rotator cuff repair using a staple. Presented at the Maui Sports Medicine Meeting, Kanapali, Maui, April 1992.
3. Wolf EM. Purely arthroscopic rotator cuff repair. In: *Current techniques in arthroscopy*. Ed 3. New York: Thieme, 1998.
4. Ellman H, Kay SP, Wirth M. Arthroscopic treatment of full-thickness rotator cuff tears: 2-7 year follow-up study. *Arthroscopy* 1993;9:195-200.
5. Essman JA, Bell RH, Askew M. Full thickness rotator cuff tear: An analysis of results. *Clin Orthop* 1991;265:170-177.
6. Paulos LE, Kody MH. Arthroscopically enhanced "mini-approach" to rotator cuff repair. *Am J Sports Med* 1994;22:19-25.
7. Levy HJ, Uribe JW, Delaney LG. Arthroscopic assisted rotator cuff repair: Preliminary results. *Arthroscopy* 1990;6:55-60.
8. Liu SH, Baker CL. Arthroscopically assisted rotator cuff repair: Correlation of functional results with integrity of the cuff. *Arthroscopy* 1994;10:54-60.
9. Neer CSI, Flatow EL. Tears of the rotator cuff: Long term

- results of anterior acromioplasty and repair. Presented at the Fourth International Conference on Surgery of the Shoulder. New York, June 1989.
10. Bjorkenheim JM, Paavolainen P, Ahovuo J, Slati P. Surgical repair of the rotator cuff and surrounding tissues: Factors influencing the results. *Clin Orthop* 1988;236:148-153.
  11. Packer NP, Calvert PT, Bayley JJ, Kessel L. Operative treatment of chronic ruptures of the rotator cuff of the shoulder. *J Bone Joint Surg Br* 1983;65:171-175.
  12. Wolfgang GL. Surgical repair of tears of the rotator cuff of the shoulder: Factors influencing the result. *J Bone Joint Surgery Am* 1974;56:14-26.
  13. Levy HJ, Gardner RD, Lemak LJ. Arthroscopic subacromial decompression in the treatment of full thickness rotator cuff tears. *Arthroscopy* 1991;7:8-13.
  14. Ellman H, Kay SP. Arthroscopic subacromial decompression for chronic impingement: Two to five year results. *J Bone Joint Surg Br* 1991;73:395-398.
  15. Esch JC, Ozerkis LR, Helgager JA, et al. Arthroscopic subacromial decompression: results according to the degree of rotator cuff tear. *Arthroscopy* 1988;4:241-249.
  16. Grant JCB, Smith CG. Age incidence of rupture of the supraspinatus tendon. *Anat Rec* 1948;100:666.
  17. Keyes EL. Observations on rupture of the supraspinatus based upon a study of seventy-three cadavers. *Ann Surg* 1933;97:241.
  18. Gartsman GM. Arthroscopic acromioplasty for lesions of the rotator cuff. *J Bone Joint Surg Am* 1990;72:169-180.
  19. Cotton RE, Rideout DF. Tears of the humeral rotator cuff: A radiologic and pathologic necropsy survey. *J Bone Joint Surg Br* 1964;46:314-328.
  20. Montgomery TJ, Yerger B, Savoic FH. Management of rotator cuff tears: A comparison of arthroscopic debridement and surgical repair. *J Shoulder Elbow Surg* 1994;3:70-78.
  21. Ogilvie-Harris DJ, Demaziere A. Arthroscopic debridement versus open repair for rotator cuff tears: A prospective cohort study. *J Bone Joint Surg Br* 1993;75:416-420.
  22. Liu SH, Baker CL. Comparison of open and arthroscopically assisted rotator cuff repair. Presented at the Annual Meeting of the American Academy of Orthopaedic Surgeons, San Francisco, February 1993.
  23. Blevins FT, Warren RF, Cavo C, et al. Arthroscopic assisted rotator cuff repair: Results using a mini-open deltoid splitting approach. *Arthroscopy* 1996;12:50-59.
  24. Warner JJ, Goitz RJ, Irrgang JJ, Groff YJ. Arthroscopic-assisted rotator cuff repair: patient selection and treatment outcome. *J Shoulder and Elbow Surg* 1997;6:463-672.
  25. Baylis RV, Wolf EM. Arthroscopic rotator cuff repair: Clinical and second look assessment. Presented at the annual meeting of the Arthroscopy Association of North America. San Francisco, CA; May, 1995.
  26. Gartsman GM, Khan M, Hammerman SM. Arthroscopic repair of full-thickness tears of the rotator cuff. *J Bone and Joint Surg Am* 1998;80:832-840.
  27. Tauro JC. Arthroscopic rotator cuff repair: Analysis of technique and results at a 2- and 3- year follow-up. *Arthroscopy* 1998;14:45-51.
  28. Gazielly DF, Gleyze P, Montagnon C, Thomas T. Arthroscopic repair of distal supraspinatus tears with Revo screw and permanent mattress sutures: A preliminary report. Annual Meeting of the American Shoulder and Elbow Surgeons, Amelia Island, FL, March 1996.
  29. Snyder SJ, Mileski RA, Karzel RP. Results of arthroscopic repair. Annual Meeting of the American Shoulder and Elbow Surgeons, Amelia Island, FL, March 1996.
  30. Weber SC. Arthroscopic versus mini- open rotator cuff repair. Arthroscopy Association of North America Fall Course, San Diego, CA, 1999.
  31. Wolf EM, Durkin RC. Arthroscopic rotator cuff repair. Two to four year follow-up. Presented at the Annual Meeting of the Arthroscopic Association of North America, San Francisco, CA, April 1995.
  32. Lundberg BJ. The correlation of clinical evaluation with operative findings and prognosis in rotator cuff rupture. In: Bayley, Kessel L, eds. *Shoulder surgery*. Berlin: Springer, 1982:35-38.
  33. Calvert PT, Packer NP, Stoker DJ, et al. Arthrography of the shoulder after operative repair of the torn rotator cuff. *J Bone Joint Surg Br* 1986;68:147-150.
  34. Harryman DT, Mack LA, Wang KY, et al. Repairs of the rotator cuff: Correlation of functional results with integrity of the cuff. *J Bone Joint Surg Am* 1991;73:982-989.
  35. Gazielly DF, Gleyze P, Montagnon C. Functional and anatomical results after rotator cuff repair. *Clin Orthop* 1994;304:43-53.
  36. Burkhart SS, Esch JC, Jolson RS. The rotator crescent and rotator cable: An anatomic description of the shoulder's "suspension bridge." *Arthroscopy* 1993;9:611-616. [Published erratum appears in *Arthroscopy* 1994;10:236.]
  37. Burkhart SS. A stepwise approach to arthroscopic rotator cuff repair based on biomechanical principles. *Arthroscopy* 2000;16:82-90.